

Red Vent Syndrome in wild Atlantic salmon – A severity field guide

Background

Wild Atlantic salmon returning with inflamed, swollen and bleeding vents have been seen in rivers throughout the UK since 2006. This condition has been called Red Vent Syndrome (RVS). This index has been developed to standardise the recording of RVS within Britain, allowing consistent reporting and monitoring. It replaces all earlier field guides. The following images show the normal vents of salmon and vents with varying degrees of RVS. Descriptions are provided to help clarify the different stages of RVS. Please use this guide when recording RVS and report these cases to the contact details below.

Contact us: For more information about RVS or to report affected fish please contact

- In England and Wales contact the Fisheries Technical Services at the **Environment Agency**. Telephone 01480 483849, or email fish.health@environment-agency.gov.uk
- In Scotland contact the Fish Health Inspectorate at **Marine Scotland**. Telephone 01224 876544 and ask for the Duty inspector, or alternatively email MS.fishhealth@scotland.gsi.gov.uk

Vent condition

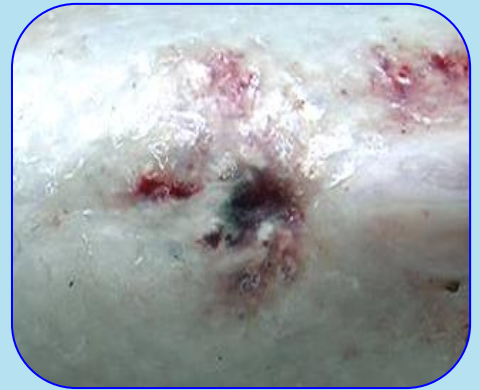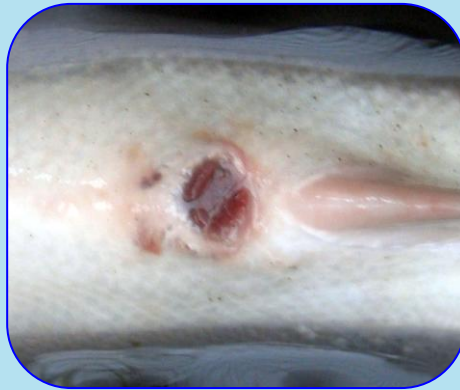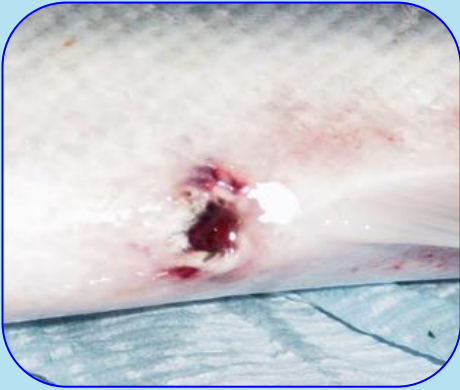
The vents of salmon can differ in appearance for natural reasons. For example, just prior to spawning the vent may become pinker and protrude slightly, but should appear clean. Some salmon may also have abrasions in the vent area or some sea lice damage as seen in the right hand image below (circled). This should not be recorded as RVS, which involves more pronounced reddening and swelling. The severity of RVS varies. Some evidence suggests that the condition of the vent can improve the longer the salmon are in fresh water. Consequently, please include date of capture, the river and location when reporting RVS cases.

Normal



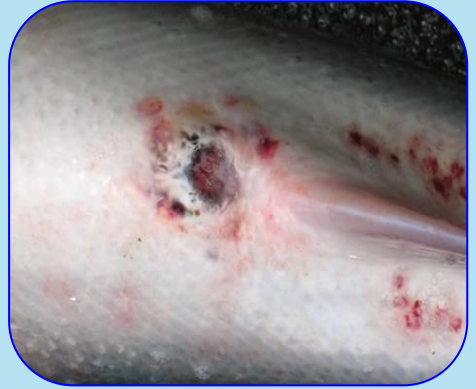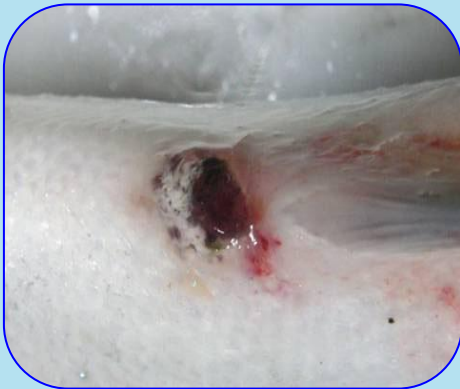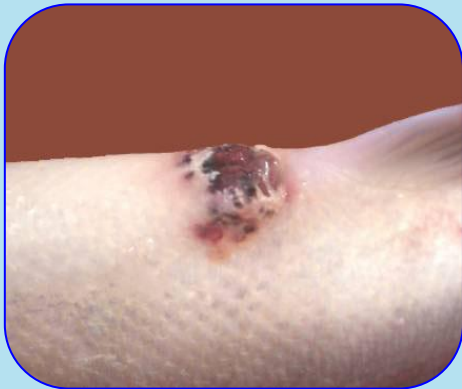Normal: Small, pink coloured vent with no evidence of swelling, lesions or haemorrhaging.

Mild RVS



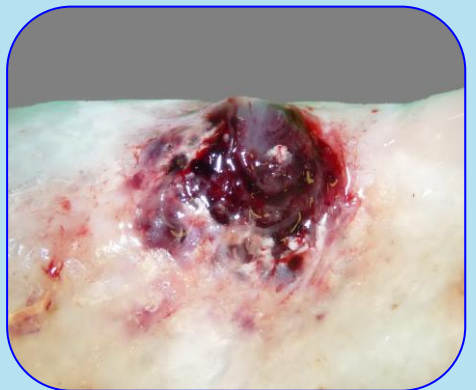
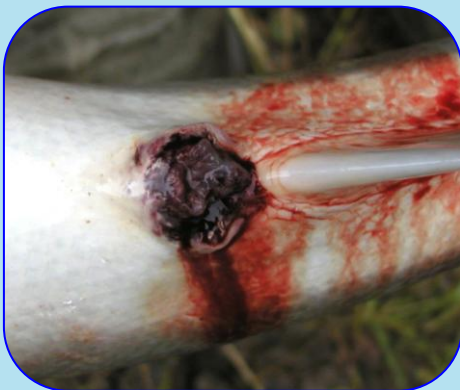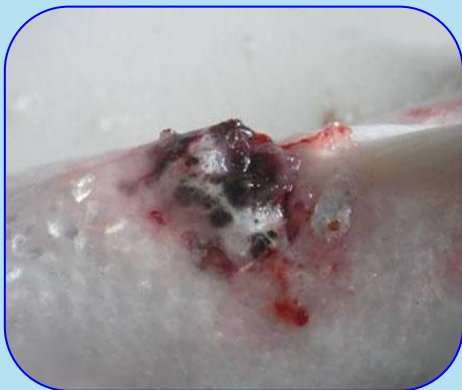Mild: Slight or no swelling. Reddening around the vent and/or a few red spots (petechial haemorrhage). No evidence of skin erosion, dead skin (necrosis) or scale loss.

Moderate RVS



Moderate: Pronounced reddening around the vent with marked swelling. Some bleeding (haemorrhage), skin erosion and scale loss may be evident.

Severe RVS



Severe: Severe swelling and/or open lesions with bleeding and/or prolapsed tissue from the vent. Eroded or dead skin (necrosis) evident around the vent. Secondary infections may also be present.